

# Intestinal obstruction

It's divided into two main groups. The paralytic obstruction i.e.: (paralytic ileus) & mechanical (dynamic) obstruction. Mechanical obstruction is further classified according to the speed of onset, the site, the nature & etiology.

**\*The speed of onset determines whether the obstruction is:**

1. Acute (usually in small bowel).
2. Chronic (as in large bowel).
3. Acute on chronic which spread from large bowel to involve the small intestine.

**\*According to site of obstruction it is classified as:**

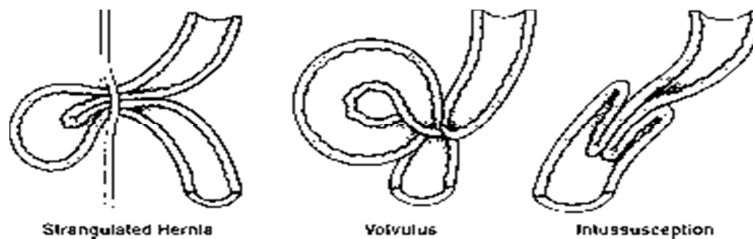
1. High small bowel obstruction.
2. Low small bowel obstruction.
3. Large bowel obstruction.

**\*According to the nature of obstruction:**

1. Simple obstruction.
2. Strangulated obstruction when there is interference with the vascular supply of the bowel.

**\*According to the etiology:**

1. Cause is in the lumen. E.g. faecal impaction, gall stone ileus, or pedunculated tumor.
2. Cause is in the wall. E.g. atresia, crohn's disease, benign or malignant tumors.
3. Cause is outside the wall. E.g. strangulated hernia, volvulus, adhesions or bands.



## Pathology

The intestine above the point of obstruction tries to overcome the obstruction by increasing peristalsis, which last from two to several days.

If the obstruction is not relieved the peristalsis gradually becomes weaker and finally it stops, the proximal part becomes distended and the obstructed intestine becomes paralyzed.

While the point distal to the obstruction exhibits normal peristalsis and absorption continue 2-3 hours following the obstruction until it becomes empty.

The proximal part is distended & distention is by two factors. (Gas & fluid)

**\*Gas comes from three sources:**

1. Swallowed atmospheric air.
2. Diffusion from blood to intestinal lumen.
3. Product of digestion & bacterial activity.
  - The gas is made up of mixture of Nitrogen & Hydrogen sulphide (H<sub>2</sub>S).
  - The O<sub>2</sub> & CO<sub>2</sub> will be absorbed to the blood stream.

**\*Fluid is made up of two sources:**

1. What the patient ingest & drink.
2. Digestive secretion: saliva, gastric juice, bile, pancreatic secretion, & succus entericus.

**The patients with intestinal obstruction get dehydration due to:**

- Diminish intake by mouth.
- Defective intestinal absorption.
- Losses due to vomiting.
- Sequestration in the bowel lumen.

\*Some time release of intestinal obstruction will be followed by death specially in case of strangulation, in which there is impairment of blood supply to the bowel wall. In strangulation the toxic substances enter the body when the viability of the bowel loop is affected, but when the obstruction is relieved these intestinal toxins pass to the level below obstruction where absorption can occur. These intestinal toxins are probably end toxins of gram negative bacilli.

So intestinal decompression is mandatory before & during operation and prophylactic antibiotics is mandatory.

**Clinical feature**

The four cardinal features of intestinal obstructions are:

1. Pain: It's colicky in nature & it's usually the first symptom.
2. Abdominal distention: It's more obvious in low intestinal obstruction & large bowel obstruction but its less in high intestinal obstruction.
3. Absolute constipation: i.e.; failure to pass feces & flatus. Sometimes there is one or two bowel motions as the lower bowel empties after the onset of the obstruction.
4. Vomiting: It occurs early in high obstruction & but late or even absent in low obstruction.

## O/E:

- The patient is dehydrated if there is large amount of vomiting had occurred.
- The patient is in pain & rolling on the bed.
- Tachycardia.
- Temperature usually is normal but if temperature is this suggest strangulation.
- Abdomen is distended & there may be visible peristalsis.
- Hernial orifices should be examined.
- Look to the abdominal wall for any previous scar which suggests adhesions or band.
- The abdomen usually is tender.
- Abdominal mass may be present in some case like carcinoma of the bowel or intussusceptions.
- PR exam. Should be done always.
- Bowel sounds are increased in early stages of obstruction but later on decrease and stops.
- In strangulated bowel tenderness and rigidity are more marked, the patient is toxic with rapid pulse and high temperature and there is leukocytosis.
- Plain abdominal X-ray (two views should be taken- erect & supine) :
  - It shows distended bowel loop with fluid levels.
  - In small intestinal obstruction the X-ray findings are: Air fluid level is in the center of the abdomen. & there is striation produced by mucosal folds.
  - In large intestinal obstruction the X-ray findings are: distended bowel loop in the periphery & there is haustration of the taenia coli.

## Treatment

- In the large bowel the obstruction is chronic, slowly, progressive & incomplete. This can be investigated further by sigmoidoscopy & Barium enema and treated electively.
- In acute cases the obstruction is of sudden onset, complete and there is high risk of strangulation. So it needs sudden surgical interference.

### **Preoperative preparations for acute obstruction are:**

1. Nasogastric tube to decompress the bowel.
2. Intra venous fluid to correct the dehydration and electrolyte imbalance. Sometime even blood is needed if the patient is anemic.
3. If there possibility of intestinal strangulation antibiotic is recommended.

### **During operation, the bowel is examined to see its viability.**

Non viability is determined by:

1. Loss of peristalsis at that segment.
2. The color becomes dark in the non-viable bowl.
3. Loss of pulsation & bleeding.

The non-viable segment can be resected safety with doing end to end anastomosis.

In large bowel the segment resected and proximal colostomy done with doing end to end anastomosis.

OR: the segment resected and both ends taken out as double burrel colostomy.

OR: only proximal colostomy done and later resection done.